Injury 56 (2025) 112321

Contents lists available at ScienceDirect

Injury

journal homepage: www.elsevier.com/locate/injury

# Ultrasound-guided percutaneous cryoneurolysis of intercostal nerves in traumatic rib fractures

Joseph D Forrester *, Simeng Wang, Alexandra A Myers, Michelle Earley, Sydney Guthrie-Baker, Anisha Abreo, Ariel W Knight, Jamie Tung

*Division of General Surgery, Department of Surgery, Stanford University, USA*

ARTICLE INFO

*Keywords:*
Rib fracture
Cryoneurolysis
Percutaneous
Acute pain

ABSTRACT

*Background:* Multimodal pain control is the cornerstone of managing acute traumatic rib fractures. We employed surgeon-administered, ultrasound-guided percutaneous cryoneurolysis of intercostal nerves (USPCNIN) as an adjunct opioid-sparing analgesic modality at the bedside.

*Methods:* This was a single-institution case series. Patients between 18–64 years of age who sustained traumatic rib fracture between ribs 3–9, deemed ineligible for surgical stabilization, and had pre-procedure numeric pain scores ≥5 underwent USPCNIN within 24 h of study enrollment by an attending chest wall surgeon. Primary outcomes were changes in daily narcotic use and numeric pain score from pre-intervention up to 30-day follow-up visits. Additional outcomes included hospital length of stay, procedure-related adverse events, and rib-specific readmission.

*Results:* Fifteen patients were identified. Median (IQR) patient age was 52 (43, 58) years and four (27 %) were female. Median (IQR) number of rib fractures was 5 (4, 8). Median (IQR) hospital length of stay was 4 (3, 7) days. Daily opioid use (measured in morphine milligram equivalents, MME) and present pain intensity (PPI) decreased significantly from pre-intervention to hospital discharge (median MME 96.5 vs. 49.5, $p = 0.043$; median PPI 10 vs. 7, $p = 0.020$). Twelve patients completed 30-day follow-up and had significantly decreased MME and PPI from hospital discharge (median MME 62.3 vs. 5, $p = 0.014$; median PPI 6.5 vs. 3, $p = 0.001$). There were no complications directly attributable to the procedure. There were no rib-specific readmissions.

*Conclusion:* USPCNIN is a minimally-invasive, bedside procedure that can be safely performed by trauma surgeons and augment pain control for acute traumatic rib fractures.

## Introduction

Rib fractures are among the most common thoracic injuries with an increasing annual incidence of inpatient admissions in past decades [1]. Inadequate pain control after rib fracture impairs respiratory mechanics and airway clearance, which can result in pulmonary complications such as pneumonia, acute respiratory distress syndrome, and empyema [2]. Chronic pain and disability present additional challenges in post-injury recovery among patients with rib fractures [3]. Gordy et al. reported that the severity of acute pain (within the first two weeks of rib fracture) was predictive of chronic pain [4]. It is therefore paramount to achieve early, effective, and durable analgesia to optimize patient outcomes. Multimodal pain management has been adopted as the cornerstone of rib fracture management, which includes scheduled non-opioid analgesics, as-needed opioids, regional or neuroaxial blockade, and surgical stabilization of rib fractures (SSRF) [5,6]. However, these modalities have limitations. Pharmaceutical interventions can have side effects or limited therapeutic windows in certain patient populations. Analgesic effects of anesthetic blocks are temporary. Some patients may have fracture patterns that do not meet criteria for SSRF or are precluded from surgery due to comorbidities or concomitant injuries [7]. There is a critical need for an additional analgesic modality that is durable and effective for these patients.

Cryoneuroloysis provides anesthesia by using extremely low temperature (−50 °C to −70 °C) that causes Wallerian degeneration of nerves, distal to the site of ablation [8]. The analgesic effect can last six months as the axon regenerates along the preserved scaffolding of perineural connective tissues [9]. Intra-thoracic cryoneurolysis is

* Corresponding author at: 300 Paster Drive H3638, Stanford, CA 94305, USA.
*E-mail addresses:* jdf1@stanford.edu (J.D. Forrester), simeng@stanford.edu (S. Wang), amyers19@stanford.edu (A.A. Myers), mjearley@stanford.edu (M. Earley), sydneygb@stanford.edu (S. Guthrie-Baker), aabreo@stanford.edu (A. Abreo), awknight@stanford.edu (A.W. Knight), jtungmd@stanford.edu (J. Tung).

https://doi.org/10.1016/j.injury.2025.112321
Accepted 30 March 2025
Available online 9 April 2025
0020-1383/© 2025 Elsevier Ltd. All rights are reserved, including those for text and data mining, AI training, and similar technologies.

increasingly used as an add-on pain control technique during surgery when the target nerve is exposed [8,10]. Cryoneurolysis of intercostal nerves (CIN) performed during SSRF was shown to decrease post-operative opioid medication use [11,12]. Minimally invasive, percutaneous CIN can be achieved under image guidance and has favorable risk-to-benefit profile as an analgesic adjunct for chest wall pain of various etiologies [13]. We employed ultrasound-guided percutaneous cryoneurolysis of intercostal nerves (USPCNIN) as an analgesic adjunct for patients with acute traumatic rib fractures who are not candidates for SSRF, hypothesizing that it can help achieve effective and durable pain control.

## Patients and methods

After institutional review board approval was obtained, patients were enrolled prospectively at a single institution between June 1st, 2022 to April 26th, 2024. Inclusion criteria for application of USPCNIN were a patient 18–64 years who sustained traumatic rib fracture between ribs 3–9 inclusive, deemed ineligible for SSRF, and had pre-procedure numeric pain scores ≥5 with deep inspiration despite receiving standard pain management per institutional multimodal pathway. Exclusion criteria were Glasgow Coma Scale <13, rib fractures located <3 cm from the transverse process, coagulopathy defined as international normalized ratio >1.5 or platelet count < 100,000/mcL, pregnancy, radiographic evidence of metastasis to ribs, inability to tolerate positioning for the procedure, or other ineligible factors at the discretion of the chest wall surgeon. The study was conducted in accordance with STROBE guidelines (Supplement).

### *Technique*

USPCNIN was performed at bedside by an attending chest wall surgeon within 24 h of study enrollment. Cryoneurolysis was achieved using a handheld system consisted of a single 20-gauge probe, iovera° Smart Tip 2190 (Pacira CryoTech, Inc., Fremont, CA). The patient was placed in prone, sitting, or lateral decubitus position. Intercostal nerves 3–9 ipsilateral to the injury were targeted in all patients. The costal angles 6–8 cm lateral from the spine were marked for insertion of the probe. After standard precautions and sterile techniques were applied, a 38-mm linear ultrasound transducer at 10–12 MHz was used to guide administration of 2 mL local anesthetic for hydrodissection of the plane between the internal intercostal muscle and the innermost intercostal muscle at the inferior intercostal groove, followed by insertion of the probe to complete a cycle of cyroneurolysis. Ultrasound and post-procedural chest XR were performed on all cases to identify any acutely worsening pneumothorax or hemothorax as a result of the procedure.

### *Outcome measures*

The primary outcomes of this study were changes in daily opioid use and patient-reported pain score obtained prior to procedure, at hospital discharge, and at 30-day follow-up. Opioid use was measured in morphine milligram equivalents (MME), which was calculated based on conversion ratio published by Center for Disease Control and Prevention [14]. Numeric pain score was reported on present pain intensity (PPI), a 0–10 numeric scale with 10 representing pain of the highest intensity. Secondary outcomes examined were hospital length of stay, 30-day mortality, need for intensive care unit (ICU) admissions, and 30-day rib specific readmissions (e.g. due to delayed hemothorax, pneumothorax, pneumonia, or pain).

### *Statistical analysis*

Patient characteristics, injury details, pre-procedure pain control information, and hospital length of stay were reported in counts and percentages for categorical variables; median and interquartile range (IQR) for continuous variables. Changes in MME and PPI at different time points were evaluated by two-sided Wilcoxon signed-rank tests with $p < 0.05$ chosen as the threshold for statistical significance. All analyses were performed using SAS 9.4 (SAS Institute Inc., Cary, NC).

## Results

Fifteen patients underwent USPCNIN within 24 h after study enrollment and 12 (80 %) of them completed 30-day follow-up. The demographic, clinical, and injury characteristics of the participants were listed in Table 1. Median (interquartile range, IQR) patient age was 52 (43, 58) years. Four patients (27 %) were female. Two patients had previously diagnosed pulmonary comorbidities (asthma) and four were active smokers. All patients had blunt injury and the most common mechanism of injury was bicycle-related (six patients, 40 %). Median (IQR) Injury Severity Score was 13 [10,14]. Seven patients (47 %) had isolated rib fractures with no other traumatic injury. Median (IQR) number of rib fractures was 5 (4, 8) and no patient had bilateral fractures. Detailed non-opioid analgesics and pain interventions of the standard institutional multimodal pathway received by each patient can be found in the Supplementary Table. Most patients received multimodal pain management including acetaminophen (93 %), gabapentin (87 %), and lidocaine patch (73 %). Three patients (20 %) received non-steroidal anti-inflammatory drugs. One patient received regional nerve block prior to USPCNIN. No anesthetic block was used after USPCNIN. Median (IQR) hospital length of stay was 4 (3,7) days. Two patients were admitted to ICU on arrival per admission criteria; one of them was transferred to ward prior to the procedure, and the other within 24 h following the procedure.

Changes in daily opioid use and patient-reported numeric pain score at three time points are reported in Table 2. From pre-intervention to hospital discharge, median (IQR) MME decreased significantly from 96.5 (32.5, 138.5) to 49.5 (15, 104) ($p = 0.043$) and similarly did median PPI from 10 (8, 10) to 7 (6, 10) ($p = 0.020$). Two patients (13 %)

**Table 1**
Patient Demographics and Clinical Characteristics.

| | | Total (N=15) |
|---|---|---|
| Age (years), median (IQR) | | 52 (43, 58) |
| Sex | Male | 11 (73%) |
| | Female | 4 (27%) |
| COPD or Asthma | | 2 (13%) |
| BMI > 30 kg/m2 | | 4 (27%) |
| Current smoker | | 4 (27%) |
| Diabetes | | 2 (13%) |
| History of chronic chest wall pain | | 0 |
| Prior rib fractures | | 2 (13%) |
| Mechanism of Injury | Fall | 2 (13%) |
| | MVC | 2 (13%) |
| | MCC | 2 (13%) |
| | BCC | 6 (40%) |
| | PVA | 2 (13%) |
| | Blunt assault | 1 (7%) |
| Injury Severity Score, median (IQR) | | 13 (10, 14) |
| Admission GCS Score, median (IQR) | | 15 (14, 15) |
| Concomitant injuries | None | 7 (47%) |
| | Intracranial hemorrhage | 1 (7%) |
| | Facial fracture | 1 (7%) |
| | Spine fracture | 2 (13%) |
| | Long bone fracture | 2 (13%) |
| | Pelvic fracture | 1 (7%) |
| | Solid organ injury | 2 (13%) |
| | BCVI | 0 |
| | More than one* | 1 (7%) |

*One patient had a long bone fracture and a solid organ injury.
**IQR** interquartile range **COPD** chronic obstructive pulmonary disease **MVC** motor vehicle collision **MCC** motorcycle collision **BCC** bicycle collision **PVA** pedestrian vehicle accident **GCS** Glasgow coma score **BCVI** blunt cerebrovascular injury.

**Table 2**
Changes in Daily Opioid Use and Pain Score(A) All Patients (B) Patients Who Completed 30-Day Follow-up.

**A)** All Patients

| | N | Pre-Intervention | Discharge | P |
|---|---|---|---|---|
| **MME** | 15 | 96.5 (32.5, 138.5) | 49.5 (15, 104) | 0.043 |
| **PPI** | | 10 (8, 10) | 7 (6, 10) | 0.020 |

**B)** Patients Who Completed 30-Day Follow-up

| | N | Pre-Intervention | Discharge | 30-Day Follow-up | P* | P** |
|---|---|---|---|---|---|---|
| **MME** | 12 | 108.1 (42.3, 161.3) | 62.3 (11.6, 99.3) | 5 (0, 42.5) | 0.003 | 0.014 |
| **PPI** | | 10 (7.5, 10) | 6.5 (5.5, 10) | 3 (2, 5.5) | <0.001 | 0.001 |

*Wilcoxon signed-rank test for pre-intervention to 30-day follow-up.
**Wilcoxon signed-rank test for discharge to 30-day follow-up.
**MME** morphine milligram equivalents; **PPI** present pain intensity.

had higher pain scores at discharge (PPI from 8 to 10), which decreased to 3 and 4 respectively at 30-day follow-up. They each had a concomitant extremity fractures (long bone and pelvis) and their opioid use decreased at discharge (MME from 138.5 to 75 and from 227.5 to 104, respectively). Among the 12 patients who completed 30-day follow-up, median MME and median PPI decreased significantly from discharge to follow-up (MME 62.3 vs. 5, $p = 0.014$; PPI 6.5 vs. 3, $p = 0.001$) and overall from pre-intervention to follow-up (MME 108.1 vs. 5, $p = 0.003$; PPI 10 vs. 3, $p < 0.001$) (Fig. 1 and Fig. 2). There were two cases of progression of existing pneumothorax or hemothorax not directly attributable to the procedure and managed successfully with chest tube drainage. There were no rib-specific readmissions or death within 30 days.

## Discussion

In this prospective case series, USPCNIN as an analgesic adjunct reduced opioid use and pain score in 15 patients who presented with acute traumatic rib fractures over the period up to 30 days following hospital discharge. Two patients' pain scores increased at discharge before they decreased at 30-day follow-up, which was in the setting of concomitant extremity injuries and reduced opioid use. No patient experienced complications attributable to the procedure or needed to be readmitted due to rib-related issues. To our knowledge, this is the largest case series to date using USPCNIN in rib fracture management and the first one to demonstrate its effects out to 30 days [15].

There is abundant evidence that multimodal pain management for rib fractures decreases in-hospital complications and prevents mortality [16,17]. USPCNIN stands out as a potentially valuable addition to the currently-available modalities for a number of reasons. It is a minimally invasive procedure that can be performed at the bedside without the need for procedural sedation or general anesthesia. It does not require extensive additional training for trauma surgeons to perform as most of them are well-versed in ultrasound-guided percutaneous access to the intercostal bundle. As a result, patients can receive the treatment of USPCNIN and its pain-control benefit within a short period of time after admission, not limited by the scheduling or staffing of interventional pain services. This may potentially decrease length of stay, time to functional recovery, and overall healthcare cost related to rib fractures although these outcomes were not directly assessed in this study. USPCNIN is generally well-tolerated with a low risk profile. Though chest percutaneous procedures have inherent risks of causing hemopneumothoraces, the two cases of progression of existing pneumothorax or hemothorax caused by rib fractures were not directly resulted from USPCNIN. Lastly, the opioid-sparing effect should continue beyond hospitalization as the pain-control property of cryoneurolysis is expected to persist up to six months during axon regeneration. In addition to minimizing side effects of opioid medications, USPCNIN may reduce outpatient opioid prescription associated with a common traumatic injury, therefore preventing the risks of opioid dependence and misuse in the era of opioid epidemic.

This study has several limitations. First, pain scores are subjective in nature and patient-reported opioid use at follow-up is susceptible to recall bias. Second, the follow-up period was limited to 30 days. Extending follow-up period can help assess the analgesic duration and identify potential long-term complications of the procedure. Neuralgia was reported in up to 30 % of patients who underwent CIN in earlier studies but not in contemporary literature [13]. Our group previously

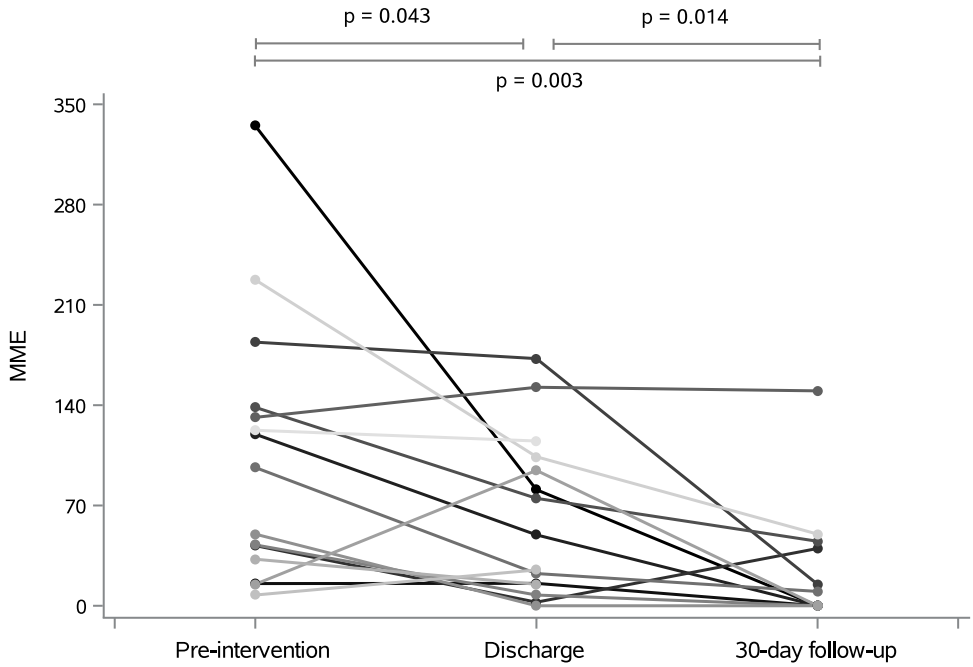


**Fig. 1.** Daily Opioid Use during Admission and at 30-Day Follow-up.
Legend: Each line represents an individual patient. MME = milligram morphine equivalents.

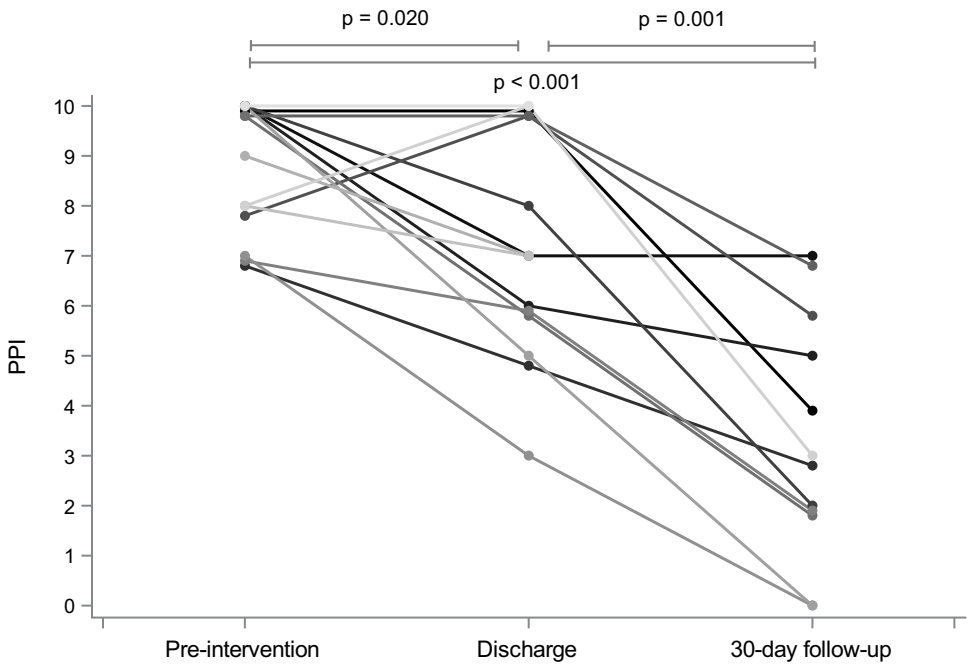


**Fig. 2.** Numeric Pain Score during Admission and at 30-Day Follow-up
Legend: Each line represents an individual patient. PPI = present pain intensity.

reported chest wall paresthesia identified at six-month follow-up in one out of 17 patients who underwent CIN during SSRF [18]. Whether these complications are associated with USPCNIN is yet to be determined. Third, in absence of a control group there may be some reduction in pain levels because of the effect of regression to the mean. There also may be reduction in pain scores, irrespective of treatment, as healing occurs and patients are weaned off opioids.

Lastly, there were a number of factors that limited the generalizability of this case series. As a pilot study, it was based on a single-institution experience and had a relatively small sample size. Patient demographics and injury characteristics were not well diversified. Most patients identified in the study were under the age of 60, male, and had mild to moderate overall injury burdens. However, this study demonstrated the feasibility, safety, and effectiveness of USPCNIN that can serve as the foundation for a larger randomized-controlled trial to fully evaluate the benefits and risks of this novel analgesic modality.

## Conclusion

USPCNIN may be an effective, minimally-invasive, bedside procedure that can be safely performed by trauma surgeons to augment conventional analgesic strategies for successful management of acute traumatic rib fractures. Further study is needed to elucidate its potential opioid-sparing property, risk profile, and long-term cost-effectiveness.

## CRediT authorship contribution statement

**Joseph D Forrester:** Conceptualization, Methodology, Validation, Formal analysis, Investigation, Resources, Writing – original draft, Writing – review & editing, Visualization, Supervision, Project administration, Funding acquisition. **Simeng Wang:** Writing – review & editing, Writing – original draft, Visualization, Validation, Methodology, Formal analysis. **Alexandra A Myers:** Software, Project administration, Formal analysis, Data curation. **Michelle Earley:** Writing – review & editing, Visualization, Validation, Software, Methodology, Formal analysis, Data curation. **Sydney Guthrie-Baker:** Project administration, Data curation. **Anisha Abreo:** Resources, Project administration, Investigation, Data curation. **Ariel W Knight:** Investigation, Data curation, Conceptualization. **Jamie Tung:** Investigation, Data curation, Conceptualization.

## Declaration of competing interest

The authors declare the following financial interests/personal relationships which may be considered as potential competing interests: Joseph D Forrester reports financial support was provided by Pacira BioSciences Inc. Joseph D Forrester reports a relationship with Varian Medical Systems Inc that includes: funding grants. Joseph D Forrester reports a relationship with Eclipse Regenysis that includes: funding grants. Joseph D Forrester reports a relationship with Costa Surgical, Inc that includes: consulting. If there are other authors, they declare that they have no known competing financial interests or personal relationships that could have appeared to influence the work reported in this paper.

## Acknowledgements and ethics statement

Funding for this work was provided by Pacira BioSciences. Dr. Forrester is also the principle investigator for an investigator-initiated clinical trial funded by Varian; principle investigator for an industry-initiated trial funded by Eclipse Regenysis, and a consultant for Costa Surgical, Inc. No other conflicts of interest are reported for any other authors.

## Supplementary materials

Supplementary material associated with this article can be found, in the online version, at doi:10.1016/j.injury.2025.112321.

## References

[1] Martin TJ, Eltorai AS, Dunn R, Varone A, Joyce MF, Kheirbek T, et al. Clinical management of rib fractures and methods for prevention of pulmonary complications: a review. Injury 2019 Jun;50(6):1159–65.
[2] Tignanelli CJ, Rix A, Napolitano LM, Hemmila MR, Ma S, Kummerfeld E. Association between adherence to evidence-based practices for treatment of patients with traumatic rib fractures and mortality rates among US trauma centers. JAMA Netw Open 2020 Mar 26;3(3):e201316.

[3] Marasco S, Lee G, Summerhayes R, Fitzgerald M, Bailey M. Quality of life after major trauma with multiple rib fractures. Injury 2015 Jan;46(1):61–5.
[4] Gordy S, Fabricant L, Ham B, Mullins R, Mayberry J. The contribution of rib fractures to chronic pain and disability. Am J Surg 2014 May;207(5):662–3. 659–62; discussion.
[5] Brasel KJ, Moore EE, Albrecht RA, deMoya M, Schreiber M, Karmy-Jones R, et al. Western Trauma association critical decisions in trauma: management of rib fractures. J Trauma Acute Care Surg 2017 Jan;82(1):200–3.
[6] Mukherjee K, Schubl SD, Tominaga G, Cantrell S, Kim B, Haines KL, et al. Non-surgical management and analgesia strategies for older adults with multiple rib fractures: a systematic review, meta-analysis, and joint practice management guideline from the Eastern association for the surgery of trauma and the chest wall injury society. J Trauma Acute Care Surg 2023 Mar 1;94(3):398–407.
[7] Kasotakis G, Hasenboehler EA, Streib EW, Patel N, Patel MB, Alarcon L, et al. Operative fixation of rib fractures after blunt trauma: a practice management guideline from the Eastern association for the surgery of trauma. J Trauma Acute Care Surg 2017 Mar;82(3):618–26.
[8] Nelson KM, Vincent RG, Bourke RS, Smith DE, Blakeley WR, Kaplan RJ, et al. Intraoperative intercostal nerve freezing to prevent postthoracotomy pain. Ann Thorac Surg 1974 Sep;18(3):280–5.
[9] Moorjani N, Zhao F, Tian Y, Liang C, Kaluba J, Maiwand MO. Effects of cryoanalgesia on post-thoracotomy pain and on the structure of intercostal nerves: a human prospective randomized trial and a histological study. Eur J Cardio-Thorac Surg Off J Eur Assoc Cardio-Thorac Surg 2001 Sep;20(3):502–7.
[10] Wood GJ, Lloyd JW, Bullingham RE, Britton BJ, Finch DR. Postoperative analgesia for day-case herniorrhaphy patients. A comparison of cryoanalgesia, paravertebral blockade and oral analgesia. Anaesthesia 1981 Jun;36(6):603–10.
[11] Bauman ZM, Loftus J, Raposo-Hadley A, Samuel S, Ernst W, Evans CH, et al. Surgical stabilization of rib fractures combined with intercostal nerve cryoablation proves to be more cost effective by reducing hospital length of stay and narcotics. Injury 2021 May 1;52(5):1128–32.
[12] Marturano MN, Thakkar V, Wang H, Cunningham KW, Lauer C, Sachdev G, et al. Intercostal nerve cryoablation during surgical stabilization of rib fractures decreases post-operative opioid use, ventilation days, and intensive care days. Injury 2023 Sep;54(9):110803.
[13] Cha PI, Min JG, Patil A, Choi J, Kothary NN, Forrester JD. Efficacy of intercostal cryoneurolysis as an analgesic adjunct for chest wall pain after surgery or trauma: systematic review. Trauma Surg Acute Care Open 2021 May;6(1):e000690.
[14] Dowell D, Ragan KR, Jones CM, Baldwin GT, Chou R. CDC clinical practice guideline for prescribing opioids for pain — United States. 2022 MMWR Recomm Rep 2022 Nov 4;71(3):1–95.
[15] Finneran Iv JJ, Gabriel RA, Swisher MW, Berndtson AE, Godat LN, Costantini TW, et al. Ultrasound-guided percutaneous intercostal nerve cryoneurolysis for analgesia following traumatic rib fracture -a case series. Korean J Anesthesiol 2020 Oct;73(5):455–9.
[16] Todd SR, McNally MM, Holcomb JB, Kozar RA, Kao LS, Gonzalez EA, et al. A multidisciplinary clinical pathway decreases rib fracture–associated infectious morbidity and mortality in high-risk trauma patients. Am J Surg 2006 Dec;192(6): 806–11.
[17] Witt CE, Bulger EM. Comprehensive approach to the management of the patient with multiple rib fractures: a review and introduction of a bundled rib fracture management protocol. Trauma Surg Acute Care Open 2017;2(1):e000064.
[18] Choi J, Min JG, Jopling JK, Meshkin S, Bessoff KE, Forrester JD. Intercostal nerve cryoablation during surgical stabilization of rib fractures. J Trauma Acute Care Surg 2021 Dec;91(6):976–80.